

# Advances in materials and concepts in fixed prosthodontics: a selection of possible treatment modalities

Daniel Edelhoff,<sup>\*1</sup> Michael Stimmelmayer,<sup>2</sup> Josef Schweiger,<sup>3</sup> M. Oliver Ahlers<sup>4,5</sup> and Jan-Frederik Güth<sup>6</sup>

## Key points

Presents innovative pre-treatment options with CAD/CAM polymers in complex rehabilitations.

Demonstrates less invasive preparation options for bonded all-ceramic veneers and occlusal onlays.

Identifies the potential and limitations of all-ceramic restorations for the abraded dentition.

Provides material selection criteria to ensure durable anterior cantilever resin-bonded FDPs and conventional FDPs.

## Abstract

The introduction of adhesive techniques in combination with translucent restorative materials has greatly influenced treatment concepts in fixed prosthodontics. Modern production technologies offer access to new polymer materials that provide innovative pre-treatment options for complex prosthetic rehabilitations. Additionally, computer-aided design and manufacturing (CAD/CAM) provides access to new ceramic types and thus extends the range of indications for metal-free restorative options. With these developments, important changes of treatment concepts in fixed prosthodontics have occurred which affect the professional life of dental practitioners with a focus on prosthetic dentistry. This article gives an overview of the advances in selected fields of fixed prosthodontics and provides support in material selection for different kinds of indications, from single-tooth restorations to fixed dental prostheses.

## Introduction

Treatment options in fixed prosthodontics have changed significantly in recent decades. Three main developments have strongly influenced these changes. First, minimally invasive treatments have increasingly become feasible in restorative dentistry, thanks to the introduction of the adhesive technique in combination with restorative materials with translucent properties comparable to those of natural teeth. Mechanical anchorage of restorations via conventional cementation,

a predominantly subtractive method, is gradually being superseded by a primarily defect-orientated additive approach. Second, modifications of conventional treatment procedures have led to the development of an economical approach to the removal of healthy tooth structure, as the planned outcome is defined in a wax-up before the treatment itself is commenced. This wax-up is then used for reference during tooth preparation. Third, digital technology delivers important additional information including 3D data, for analysis, diagnostics, communication, restorative designs and treatment planning, improving reproducibility. Also, the computer-aided design/manufacturing (CAD/CAM) process facilitates more standardised fabrication processes and quality improvements in materials, and provides access to new materials offering favourable options during the pre-treatment period as well as for subsequent definitive restorations. Similarly, the introduction of cantilever resin-bonded fixed dental prostheses and implants permits the preservation of tooth structure for teeth as abutment teeth.

This article demonstrates the advances in materials and strategies in fixed prosthodontics by discussing a selection of possible treatment modalities and supports these concepts by citing the available scientific literature.

## Background

At present, conventional treatment with metal-based crowns and fixed dental prostheses (FDPs) are considered the gold standard for clinical success and survival.<sup>1</sup> However, the extensive removal of tooth structure associated with full coverage crowns and FDPs on prepared abutment teeth remains a major drawback. A retrospective clinical study has demonstrated that the 15-year survival probability of vital pulps was 81.2% in metal-ceramic single crowns and only 66.2% in FDP abutments.<sup>2</sup> Foster found an endodontic complication rate of 21% for FDP abutments after six years.<sup>3</sup> An initial quantification of hard tissue removal with different preparation configurations revealed that up to 72% of the clinical crown will be removed in full crown preparations in the anterior and posterior regions.<sup>4,5</sup> In contrast, all-ceramic anterior veneer preparations are associated with removing tooth structure in

<sup>1</sup>Director and Chair, Department of Prosthetic Dentistry, University Hospital, LMU, Munich, Germany; <sup>2</sup>Associate Professor, Department of Prosthetic Dentistry, University Hospital, LMU, Munich, Germany; <sup>3</sup>Dental Technician, Head of Dental Laboratory, Department of Prosthetic Dentistry, University Hospital, LMU, Munich, Germany; <sup>4</sup>Department of Prosthetic Dentistry, Centre for Dental and Oral Medicine, University Medical Centre Hamburg-Eppendorf, University of Hamburg, Hamburg, Germany; <sup>5</sup>Director, CMD-Centre Hamburg-Eppendorf, Hamburg, Germany; <sup>6</sup>Associate Professor, Department of Prosthetic Dentistry, University Hospital, LMU, Munich, Germany.  
Correspondence to: Daniel Edelhoff  
Email: daniel.edelhoff@med.uni-muenchen.de

Refereed Paper.

Accepted 7 January 2018

DOI:10.1038/s41415-019-0265-z

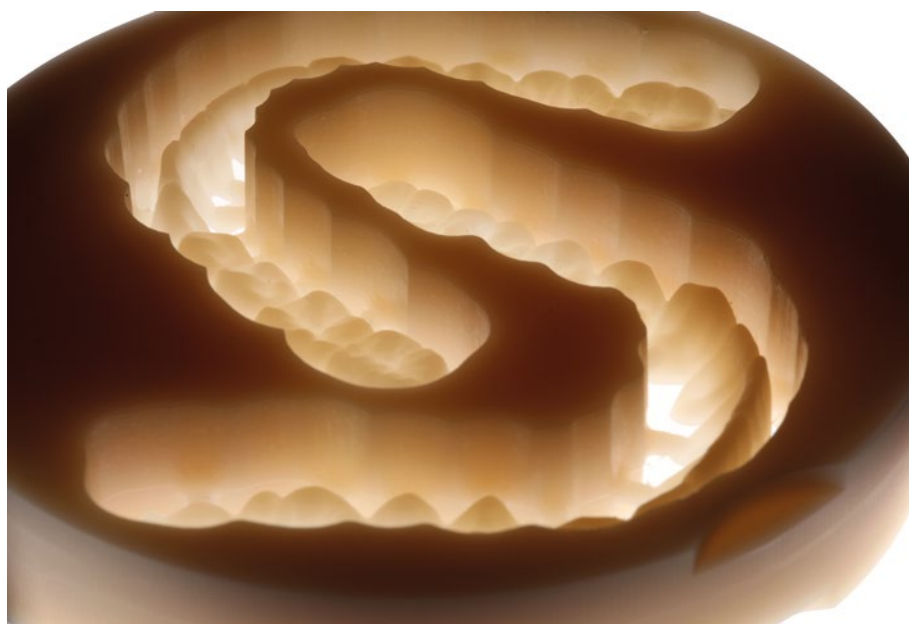the amount of between 7% (partial veneers) and 30% (extended veneers).<sup>4</sup> For occlusal onlays with proximal extensions, 32% of the tooth structure was removed.<sup>5</sup> These findings were confirmed in a study that used state-of-the-art measuring techniques and are increasingly affecting treatment decisions in prosthodontics.<sup>6</sup>

Several *in vitro* studies on endodontically-treated teeth have found that preserving greater amounts of natural tooth structure has a significant positive effect on fracture resistance in all tooth types.<sup>7,8</sup> Up to 45% more tooth structure can be preserved by opting for partial rather than complete coverage when restoring endodontically-treated molars.<sup>9</sup> Similar results were found for retainer preparations for resin-bonded FDPs and attachments.<sup>10,11</sup>

It is noteworthy that clinical studies on all-ceramic partial coverage crowns have shown no or very low endodontic complication rates, at observation periods between seven and 12.6 years, compared to studies on metal-ceramic full coverage crowns.<sup>12</sup> For veneer restorations, the rate of endodontic complications was as low as 2.51% after an observation period of 20 years.<sup>13</sup> Hence, less invasive preparation and restoration designs appear to have a favourable effect on the vitality of restored teeth. Against this background, fixed prosthodontics has been undergoing a paradigm shift towards less invasive methods in recent years. Prosthetic concepts have also become increasingly well-differentiated in recent decades.<sup>10,14,15</sup>

Predominantly subtractive concepts, to provide mechanical retention for traditionally cemented restorations, are being replaced by less invasive, primarily defect-orientated procedures wherever feasible.<sup>16</sup> In the case of pronounced dental hard tissue loss, additive approaches offer innovative reversible pre-treatment options and functional restorations.<sup>17,18</sup> In addition, modifications are being made to traditional procedures, such as defining the treatment goal in the lead-up to the treatment itself with the aid of a diagnostic wax-up.<sup>19</sup> The wax-up provides orientation for tooth preparation and a more economical approach when it comes to removing healthy dental hard tissue.<sup>20</sup>

This article intends to describe innovative pre-treatment options and methods that allow the removal of hard tissues to be substantially reduced. Metal-free CAD/CAM materials will be presented and discussed, focusing on selected polymers and all-ceramic materials.



**Fig. 1** Industrial prefabricated CAD/CAM disc made of tooth-coloured polycarbonate (Temp Premium Flexible; Zirkozahn, Gais, Italy) after milling two fully-contoured removable splints

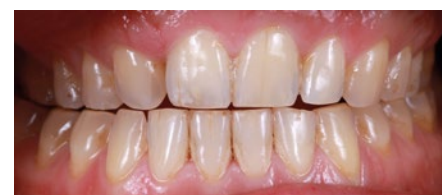### Innovative pre-treatment with CAD/CAM polymers

Pre-treatment with occlusal splints is an important step in a structured concept for complex prosthetic rehabilitations and serves to determine and stabilise a physiological condylar position. Furthermore, it permits evaluating acceptance of the intended vertical dimension. Conventional positional splints are a proven, established and relatively low cost pre-treatment. Their chemical composition allows the splints to be modified to follow adaptive changes in condylar position. However, the willingness of patients to wear conventional splints during daytime is limited, mostly due to aesthetic and phonetic restrictions, limiting their efficiency.<sup>21</sup> In addition, conventional positioning splints are generally provided for only one jaw. In bimaxillary restorative treatments, therefore, they attempt to represent the entire change in vertical dimension in a single appliance and cannot simulate the position of the occlusal plane of the subsequent restoration. Despite these limitations, conventional relaxation and positioning splints continue to be the method of choice for initial pain relief and functional rehabilitation.

With the introduction of CAD/CAM-milled polymers, novel alternatives to splints have become available. Designed according to a diagnostic wax-up and milled and finished to full contour from tooth-coloured

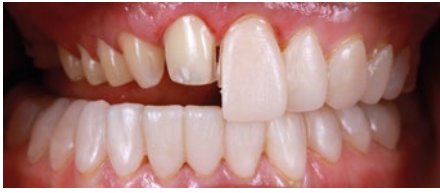

**Fig. 2** Fully-contoured CAD/CAM occlusal splints for bimaxillary application (maxilla and mandible) after separation from the polycarbonate disc. The material exhibits an extremely high degree of flexibility and, even when extremely thin (0.3 mm), has a high fracture resistance

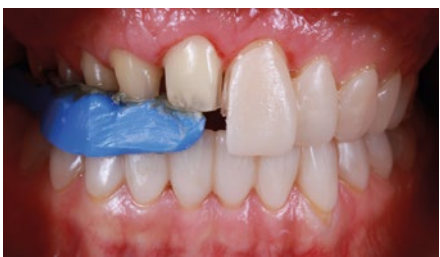

**Fig. 3** Preoperative frontal view of a female patient with a right cleft lip and palate. Tooth 12 is missing and the dentition exhibits severe tooth wear that has led to a change in intercuspal position and a decrease in the vertical dimension of occlusion

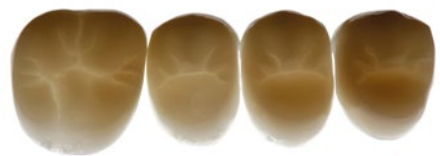polycarbonate, these splints approximate the definitive restoration in terms of function and aesthetics (Fig. 1). Removable monomaxillary or bimaxillary full contour splints provide the option of conservative, surgical, periodontal and restorative interventions beneath them



**Fig. 4** After a successful clinical evaluation of aesthetics and function over at least three months, the transition to the definitive restoration can proceed segment by segment, using the reciprocal transfer method for the evaluated jaw relation. The right quadrant was prepared and the maxillary splint separated in half with a separating disk

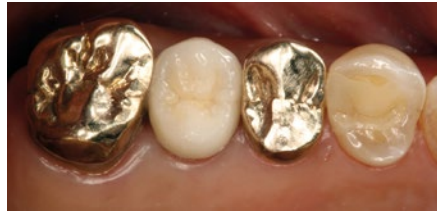

**Fig. 5** With the left half of the splint inserted in the still unprepared left quadrant, the jaw relation was registered using a high precision bisacrylate registration material (LuxaBite; DMG, Hamburg, Germany), which can be corrected with Aluwax (American Dental Systems, Vaterstetten, Germany). Limitations of this technique exist in patients who suffer from instable temporomandibular joints or who are occlusion-sensitive. In these cases, the techniques featured in the subsequent illustrations should be used

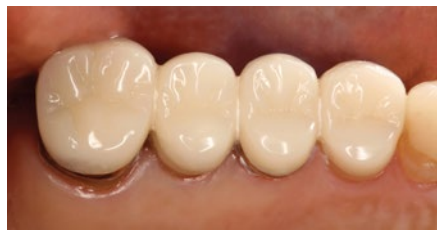

**Fig. 6** CAD/CAM repositioning onlays made of PMMA (TeliCAD; Ivoclar Vivadent, Schaan, Liechtenstein). These extra thin additive PMMA restorations can be bonded to existing restorations for occlusal correction as a fixed pre-treatment and simultaneously for a 'test drive' of the new occlusion

without adverse effects on the newly defined aesthetic and functional situation (Figs 2 and 3). At the end of the 'test drive' period, a segmented transfer to the final restoration can be performed, facilitating the treatment of complex rehabilitations (Figs 4 and 5).<sup>17</sup>



**Fig. 7** Preoperative situation of a patient seeking treatment for bite correction because of severe pain in function as a consequence of a generalised malocclusion



**Fig. 8** Occlusal PMMA veneers bonded to existing restorations. Before adhesive placement with a low viscosity resin cement, the existing metal ceramic restoration with gold margins were tribochemically air-abraded (CoJet; 3M, Seefeld, Germany), then cleaned and coated with a primer

An additional pre-treatment option is the application of polymethyl methacrylate (PMMA) repositioning onlays and veneers, bonded to the compromised tooth or existing restorations (Figs 6, 7 and 8). They can be made conventionally or by CAD/CAM.<sup>22,23</sup> Given the higher edge stability compared to ceramics, polymer-based materials can be milled to very thin layers of up to 0.3 mm and can thus serve as pure additive restorations without any tooth preparation.<sup>23</sup> However, this pre-treatment option is more complicated because the bonded PMMA restorations are difficult to modify intraorally, their reversibility is limited, and they are relatively expensive. Nevertheless, because the contours of these temporary restorations are identical to the intended restored situation and because they are inserted permanently, patients can even eat with them, which makes the evaluation period as realistic and effective as possible.

According to the authors' experience, both monomaxillary and bimaxillary full contour simulation splints, as well as repositioning onlays and repositioning veneers, enjoy substantially better patient acceptance than conventional positional splints and provide new 'test drive' options to explore the aesthetics, phonetics and function of complex prosthetic

rehabilitations. They can serve to identify the most adequate occlusion concept, especially in patients sensitive to occlusal changes. In complex prosthetic rehabilitations, they permit a conversion to the definitive restoration, a segment at a time (Fig. 9). However, relevant clinical studies are still absent.

## Conversion to definitive all-ceramic restorations

### All-ceramic anterior veneers

Encouraged by positive long-term clinical results, there has been a steady expansion of the range of indications for all-ceramic veneers, even going so far as to re-evaluate previous contraindications to open up possible new fields of application.<sup>24,25,26,27,28,29</sup> Against this background, ceramic veneers have shed their reputation of being purely aesthetic adjuncts, turning into a serious treatment alternative, in addition to conventional, far more invasive types of restorations.<sup>30,31,32</sup> Today, veneers are also used to restore the biomechanics of the dentition, establish adequate function, mask highly discoloured endodontically-treated teeth, and for other purposes.<sup>33</sup> Silicate ceramic materials are the material of choice to replace lost natural enamel thanks to their enamel-like optical and mechanical properties.<sup>34,35</sup> However, veneer preparation, provisionalisation and adhesive bonding place greater demands on the operator's skills than complete-coverage crown preparation and conventional cementation. Enamel preservation represents a determining factor for the success of a veneer restoration.<sup>36,37</sup> Therefore, veneers should be designed using a mainly additive approach.

Veneer preparations are subject to stringent principles, but they still offer a high degree of flexibility in terms of the restorative design, depending on the clinical situation (tooth position, degree of destruction, occlusal conditions, periodontal surroundings etc).<sup>38,39</sup> This is true for both the incisal design and for its interproximal extension.<sup>38,24</sup> Preparing a palatal chamfer offers the highest degree of freedom in positioning the incisal edge, which is particularly important if a large amount of hard tissue has been lost.<sup>38,39,40</sup>

Similar considerations apply to the interproximal extension of the preparation (Fig. 10).<sup>35,24</sup> If the popular medium wrap design is used, the contact area, and thus the width of the existing tooth, are maintained and, consequently, the height is determined by the defined width to height ratio (Fig. 11).






Fig. 9 Overview of the pre-treatment options for complex prosthetic rehabilitations with major changes in aesthetics and function, and the transition to definitive restorations

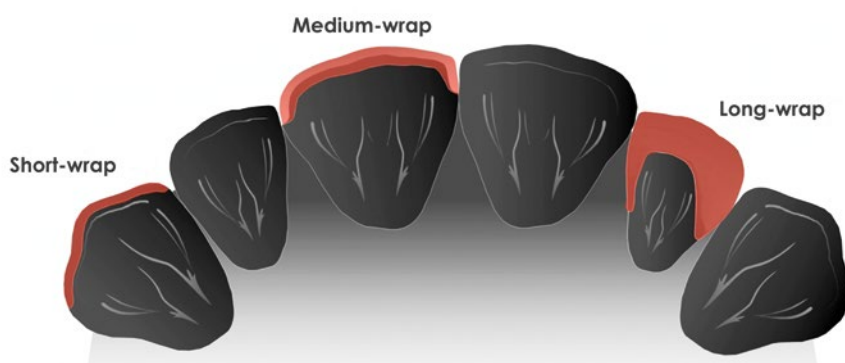


Fig. 10 Design options for the interproximal extension. Left to right, with increasing levels of invasiveness. Short wrap design: easy to implement, but with a visible adhesive joint. Medium wrap design: retains the contact point, with the adhesive joint not visible. Long wrap design: removes the contact point and requires a deeper (approximately two thirds) interproximal preparation

By contrast, a long wrap design eliminates the contact areas due to their deep interproximal extension, offering considerably more scope for variation regarding the shape and position of the restoration (Fig. 12). The long wrap design is therefore advantageous in severe discolouration, diastemas, extensive shape modifications, slide midline corrections, black triangles and large fillings. Furthermore, the long wrap design is recommended for veneers in the immediate vicinity of crowns, as it allows the contact area between the two restorations to be executed in ceramics. Interproximal

preparation can be conveniently accomplished with oscillating preparation instruments (for example, Sonic Line; Komet Dental, Lemgo, Germany) and Soflex discs (2382 M; 3M, Seefeld, Germany).<sup>41</sup> In periodontally compromised situations, the long wrap design may be combined with a horizontal insertion axis,<sup>42</sup> eliminating the need for an extensive reduction of the coronal tooth structure. The width can be smaller cervically than incisally. Substantial amounts of hard tissue can be preserved with this configuration. On the downside, however, the clinical and technical

implementation of this technique is difficult.

Circular preparation designs (360° veneers), also known as ‘full wrap’ veneer designs, are particularly recommended for complex cases that require increasing the vertical dimension of occlusion to close the resultant free space on the palatal aspect of the maxillary anterior teeth (Fig. 13). Essentially, a diagnostic template or silicone mould should be manufactured from the wax-up and used as a guide during tooth preparation, reducing the amount of tissue removed, by taking into account the previously defined external contour of the future veneer (Fig. 14).<sup>35,37,43</sup> If severe discolouration is present, the preparation may be slightly deeper to provide sufficient scope for masking the tooth.<sup>33</sup> Luting composites can also be used to slightly modify the final colour of ceramic veneers.<sup>44</sup> In a retrospective ten-year cohort study, these veneers have been shown to offer a 93.5% survival probability.<sup>13</sup> First interim results of a prospective clinical study on veneers with a long wrap design have been promising; however, no sufficient data are as yet available on either long wrap or full wrap veneers.<sup>45</sup> The survival rates of ceramic veneers are also influenced by other parameters, including the amount of available enamel, the optical and mechanical properties of the material used, the preparation design, tooth function and occlusion, the degree of destruction and the vitality of the tooth to be treated (vital or endodontically-treated), as well as the level of experience of the restorative team.<sup>13,31,36,37</sup>

All-ceramic occlusal onlays

Adhesively connected all-ceramic occlusal onlays are a reliable treatment option for the posterior region.<sup>46,47</sup> In this context, it should be borne in mind that most clinical long-term studies are based on leucite-reinforced glass ceramics, whereas considerably stronger ceramic materials based on lithium disilicate

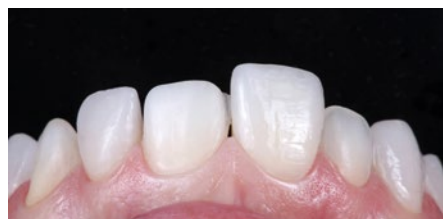

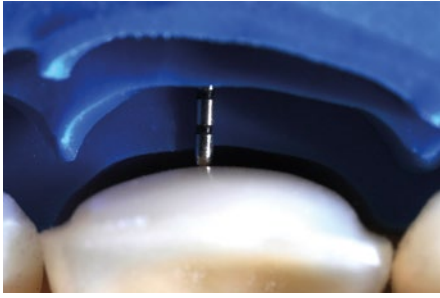
Fig. 11 Veneer preparation in medium wrap design, preserving the contact points, and try-in of definitive feldspathic veneers, sintered on refractory dies (laboratory procedures: Otto Prandtner, MDT, Munich, Germany)

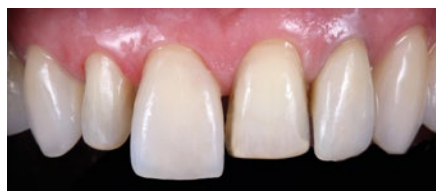

Fig. 12 Veneer preparation in long wrap design, opening the contact points, and try-in of the definitive veneers made of feldspathic ceramics using the sintering technique on refractory dies (laboratory procedures: Otto Prandtner, MDT, Munich, Germany)

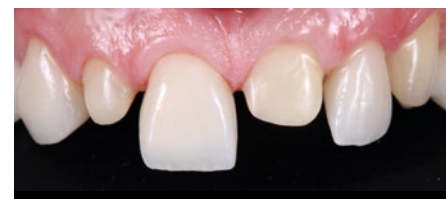

Fig. 13 Veneer preparation in full wrap design (360° veneers) and try-in of the definitive monolithic bichromatic veneers made of lithium disilicate ceramic (IPS e.max Press Multi; Ivoclar Vivadent; Otto Prandtner, MDT, Munich, Germany)

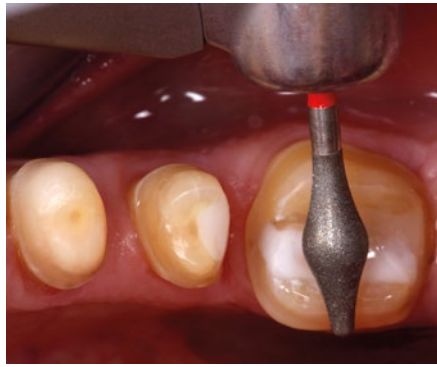


**Fig. 14** Template-guided veneer preparation. The silicon index was made on the wax-up and then seated on the prepared teeth to control the removal of hard tissue against to the planned contour of the definitive restoration using a special probe featuring a millimetre scale (CP-15UNC, University of North Carolina; Hu-Friedy, Tuttlingen, Germany)

are available today.<sup>12,48</sup> With the decreasing incidence of caries, accompanied by an increasing incidence of biocorrosive defects, including in generalised form, changed defect morphologies of the dental hard tissue are gaining in importance.<sup>49,50</sup> Thus, the requirement profile for minimally invasive, defect-orientated, adhesively-cemented single-tooth restorations has changed. Restorative treatment in the posterior region now focuses increasingly on occlusal defects, seeking to restore adequate function, aesthetics and biomechanics, and to help prevent further pathological wear.

In view of the sometimes extreme changes in occlusal contour due to tooth wear, adhesively-cemented occlusal onlays made of high-strength glass ceramics are a more desirable type of restoration than conventional full crowns, which are twice as invasive.<sup>5</sup> As they permit a defect-orientated preparation and eliminate the need for a retentive preparation design, all-ceramic onlays are a sensible treatment option and avoid conventional invasive methods.<sup>14,51</sup> The supragingival preparation margins of occlusal onlays offer numerous advantages in terms of better control during preparation, reduced loss of dental hard tissue, less or no traumatic interference with the marginal gingiva, easier conventional and digital impression-taking, more available enamel for bonding and well-controlled adhesive cementation, possibly under rubber dam (Figs 15 and 16).

Since the introduction of lithium disilicate, the recommended preparation depths for glass ceramic onlays have been reduced significantly. Today, a minimum occlusal thickness of 1 mm is recommended for monolithic



**Fig. 15** Preparation of an occlusal plateau for a lithium disilicate ceramic occlusal onlay. The specific geometry of the abrasive body (here: OccluShaper as finisher, Komet Dental, Lemgo, Germany) creates anatomically-shaped convex cusp support for the future occlusal onlay while leaving enough space in the central fissure to implement an immediate side shift (ISS) during dynamic occlusion

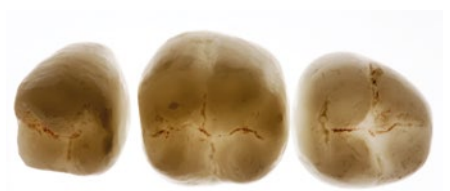restorations (staining technique) (Figs 17 and 18). Discussions are currently underway about further reductions in layer thickness if appropriate enamel support is present.<sup>14,48</sup>

Glass ceramic onlays appear to be ideally suited for rebuilding abraded and eroded posterior teeth because they offer enamel-like properties and a favourable interface behaviour.<sup>51</sup> They allow particularly gentle preparation of the tooth structure, as long as the preparation does not extend beyond the equator into the infrabulge (Fig. 16). Consequently, these onlays can help avoid conventional, much more invasive prosthetic procedures. It is essential for the preparation margins to be located predominantly in enamel. Extensive silicate ceramic onlays have displayed a favourable stress response pattern and with almost exclusively compressive forces at the interface in *in vitro* studies.<sup>51</sup> However, all transitions should be rounded and soft to prevent stress peaks within the restoration (Fig. 15).<sup>52</sup>

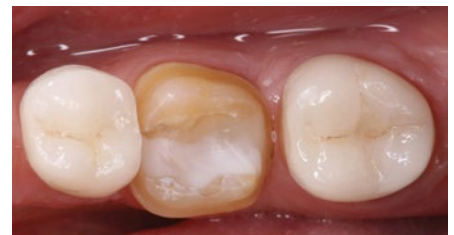It is generally useful to distinguish between pure onlays, involving only occlusal surfaces, and onlay veneers, involving the vestibular surface. The latter are indicated if a major shade modification in the aesthetic region (premolar) is required (Fig. 15).<sup>23</sup> In a controlled prospective clinical study, silicate ceramic onlays showed satisfactory long-term results after 12 years. They are also suited for use in extensive tooth structure defects.<sup>53</sup> Another clinical study with an observation



**Fig. 16** Occlusal onlay preparations are associated with a gentle removal of tooth structure, especially if the preparation does not extend beyond the equator into the infrabulge (red marked area)



**Fig. 17** Monolithic occlusal onlays made of IPS e.max Press (degree of turbidity: HT) with an occlusal thickness of 1 mm and a 0.5 mm circular border (laboratory procedures: Otto Prandner, MDT, Munich, Germany)



**Fig. 18** Try-in of the lithium disilicate ceramic occlusal onlays (IPS e.max Press, degree of turbidity: HT) with a colour-keyed dyed try-in paste (Variolink Esthetic, Try-in, colour: warm; Ivoclar Vivadent)

period of 12.6 years revealed failure rates of 20.9% in vital teeth and 39% in endodontically-treated teeth.<sup>47</sup>

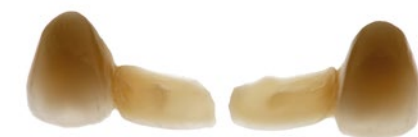### Resin-bonded anterior all-ceramic FDPs

Resin-bonded fixed dental prostheses (RBFDPs) in the anterior region were first described in the 1970s.<sup>54</sup> In a literature review, RBFDPs comprising two retainers showed a significantly lower probability of survival than full crown abutments over a period of ten years.<sup>1</sup> However, it should be borne in mind that anterior maxillary teeth are considered to be particularly vulnerable to vitality loss when used as full crown abutments in conventional FDPs.<sup>2</sup> The tooth structure removal on anterior maxillary central incisors was measured to be up to 72.1% for full crown abutments and only

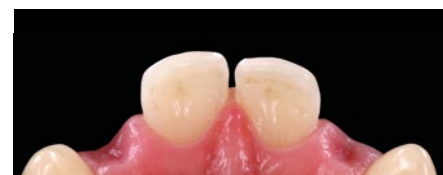12.4% after preparation of wing retainers for an RBFDP.<sup>4</sup> With the introduction of metal-based cantilever RBFDPs (cRBFDPs) in the 1980s, invasiveness levels were further reduced and the need for unphysiological splinting of abutment teeth was eliminated.<sup>55,56</sup> In the anterior region, cRBFDPs were identified to have a lower clinical failure rate than two retainer RBFDPs.<sup>57,58</sup> The principles of minimally invasive treatment also favour cRBFDPs.<sup>58</sup> In the 1990s, glass-infiltrated aluminium oxide ceramics were used for the first time in a clinical study to manufacture all ceramic RBFDPs with two retainers.<sup>59</sup> With greater popularity and better access to CAD/CAM technology, zirconia-based cRBFDPs became the therapy of choice where metal-free cRBFDPs are indicated.<sup>60,61</sup>

Today, most cRBFDPs are made with frameworks made of materials with a high modulus of elasticity, such as base-metal alloys or zirconia ceramics (Fig. 19). They are used in the anterior region as an alternative to implant-supported restorations for single teeth if implant treatment is contraindicated, extensive surgical interventions should be avoided, the space available is insufficient for implant treatment, the patient is too young or too old, or if an implant is simply not wanted.<sup>55,61</sup> In a clinical trial investigating the impact of complications of anterior single-tooth restorations, the oral health-related quality of life was similar irrespective of whether implant-supported single crowns or cRBFDPs were used.<sup>62</sup>

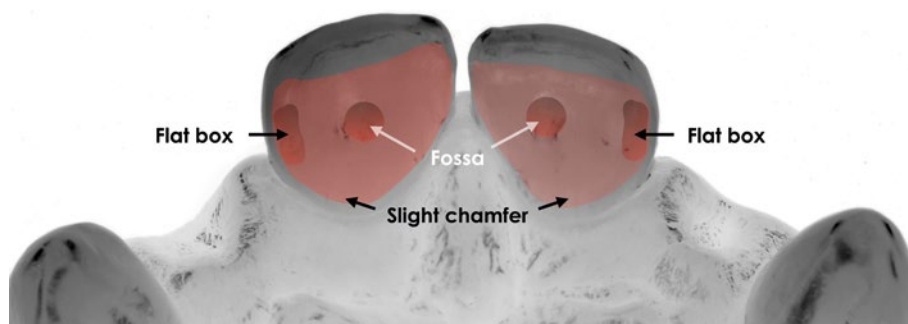
One of the most important indications is in the anterior region of the maxilla, as the highest incidence of dental agenesis is reported to affect maxillary lateral incisors, with a higher prevalence in female than male patients.<sup>63</sup> In the same meta-analysis, bilateral agenesis of maxillary lateral incisors was found more frequently than unilateral agenesis (Fig. 20). If a maxillary lateral incisor is missing, central incisors will be the abutments of choice for cRBFDPs due to their larger proximal contact area (PCA) (Figs 20 and 21).<sup>64</sup> Removing between 0.5 mm and 0.7 mm of tooth structure is recommended in preparation for the wing-shaped retainer, with either a slight chamfer or slight rounded shoulder as a finishing line. Instead of retentive grooves associated with metal-based RBFDPs, a flat proximal box 0.5 mm in depth and 2 × 2 mm in width is recommended at the connector side for pontics of all-ceramic cRBFDPs (Fig. 21).<sup>60,65</sup> Additional requirements include healthy



**Fig. 19** CAD/CAM zirconia-based cantilever resin-bonded fixed dental prosthesis (cRBFDPs) for the replacement of two missing maxillary lateral incisors (left and right) in a young female patient (laboratory procedures: Otto Prandtner, MDT, Munich, Germany)



**Fig. 20** Post-orthodontic palatal view of the anterior tooth display of a young female patient with bilateral agenesis of the maxillary lateral incisors. The recipient site of the pontic had been pre-treated for an improved emergence profile



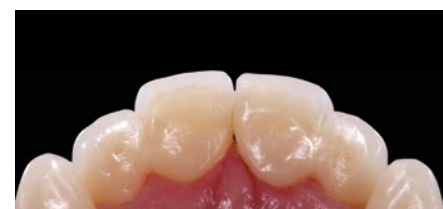**Fig. 21** For zirconia-based cantilevered RBFDPs, a flat proximal box 0.5 mm in depth and 2 × 2 mm in width is recommended at the connector side for the pontic



**Fig. 22** For a reliable bond to the zirconia wing, the internal surface was air-abraded with carborundum (50 μm grain) at 1 bar of pressure. For better control of the air abrasion process, a black marker was applied to the internal surface of the wing. In a second step, the air-abraded zirconia was cleaned and a MDP primer was applied ahead of the luting composite

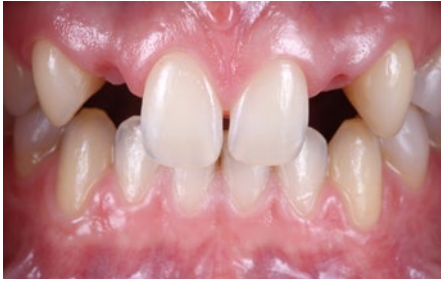abutment teeth that are primarily free of both caries and fillings, enough interocclusal space (approximately 0.8 mm) and sufficient amounts of enamel.<sup>61</sup> Where central incisors show major carious lesions, extended fillings, endodontic treatment or similar, the canine can be selected as the abutment tooth for cRBFDPs.

One of the most frequent minor complications is debonding. A reliable procedure for binding to either tooth hard tissue or zirconia is considered the most important prerequisite for the long-term clinical success of zirconia-based cRBFDPs.<sup>66</sup>

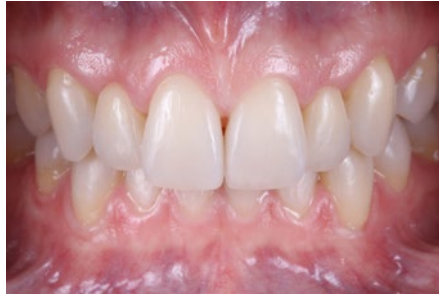

**Fig. 23** Postoperative palatal view after the adhesive placement of two zirconia cRBFDPs with an ovate pontic design. Since the distal contact area of the pontics can be accessed by dental floss, hygiene procedures are simplified compared to two retainer RBFDPs

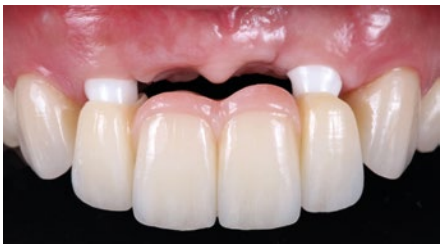



**Fig. 24** Post-orthodontic frontal view of a young female patient with congenitally missing maxillary lateral incisors (orthodontic procedures: Professor A. Wichelhaus, LMU Munich, Germany)



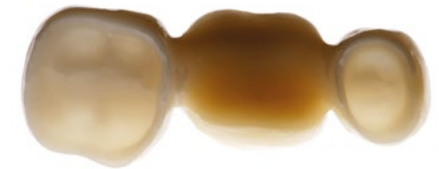**Fig. 25** Postoperative frontal view after adhesive insertion of the zirconia cRBFDPs restorations. Both canines and centrals received bonded no-prep feldspathic veneer restorations made using the refractory-die technique (laboratory procedures: Otto Prandtner, MDT, Munich, Germany)



**Fig. 27** Try-in of the four-unit zirconia-based FDP on two implants (Screw-line, 3.8/13 mm; Camlog, Wimsheim, Germany) in the lateral incisor positions 12 and 22, with zirconia hybrid abutments

Where bonding to enamel represents a predictable and well-established procedure, different methods to generate a reliable adhesion to zirconia surfaces are described.<sup>67</sup> Based on the results of a systematic review, the physico-chemical conditioning of zirconia, including moderate airborne particle abrasion and the use of MDP-based resin cements, were found to produce reliable adhesion (Figs 22 and 23).<sup>68</sup> Following these protocols, this type of minimally invasive restoration can satisfy high aesthetic demands while requiring relatively little treatment time (Figs 24 and 25). Since the preparation takes place almost exclusively within the enamel, local anaesthetics are usually not required.

Data from clinical studies on zirconia cRBFDPs show excellent clinical results. In a four-year clinical study, with 15 zirconia cRBFDPs, a survival rate of 100% was reported.<sup>69</sup> Two early debondings could be successfully reattached. In a clinical long-term study of a total of 108 anterior zirconia cRBFDPs, 75 in the maxilla and 33 in the mandible, a ten-year survival rate of 98.2% and a corresponding success rate of 92.0% were reported. Six debondings and one restoration

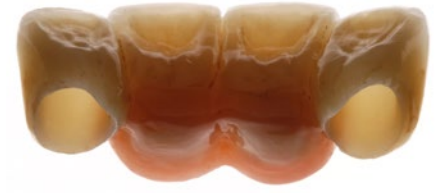

**Fig. 28** Basal view of a posterior three-unit FDP with a CAD/CAM zirconia framework (3Y-TZP, Lava Plus; 3M) and manually-sintered ceramic veneer (IPS e.max Ceram; Ivoclar Vivadent) to replace tooth 36 (laboratory procedures: Otto Prandtner, MDT, Munich, Germany)

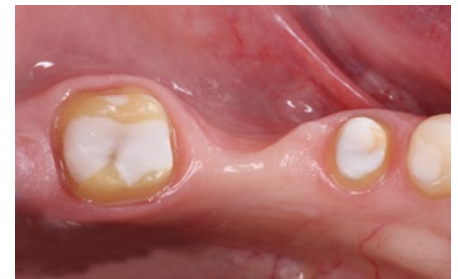loss were recorded; all debonded zirconia cRBFDPs could be rebonded.<sup>10</sup> In carefully selected cases, lithium disilicate ceramics might be suitable as a framework material for cRBFDPs.<sup>70</sup>

### Conventional FDPs made of zirconia

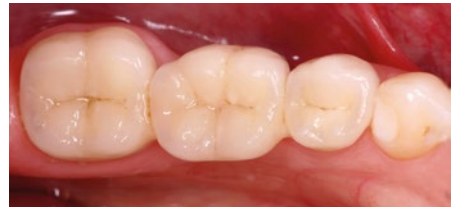Lithium disilicate ceramics was introduced in 1998 as a reliable metal-free material for different types of single-tooth restorations. For single crowns, long-term clinical survival rates comparable to metal ceramic crowns have been reported.<sup>71,72,73</sup> In contrast, conventional three-unit FDPs made of lithium disilicate ceramics are recommended for only limited indications (anterior dentition with second premolar as distalmost abutment), and survival rates were strongly correlated with the framework design, veneered or monolithic.<sup>74,75,76</sup> The introduction of CAD/CAM technology gave rise to the first generation of yttrium-stabilised polycrystalline tetragonal zirconia (3Y-TZP), with significant higher flexural strengths than all dental glass or oxide ceramics available at this time.<sup>77</sup> Because



**Fig. 26** Palatal view of a four-unit FDP with a CAD/CAM zirconia framework and a manually sintered ceramic veneer (IPS e.max ZirCAD LT [3Y-TZP]/IPS e.max Ceram; Ivoclar Vivadent). The ceramic gingiva replica was also sintered onto the zirconia framework (laboratory procedures: Oliver Brix, CDT, Bad Homburg, Germany)

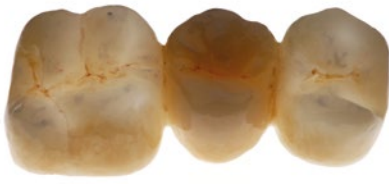

**Fig. 29** Abutment teeth 35 and 37 prepared for a three-unit zirconia FDP with ceramic veneer

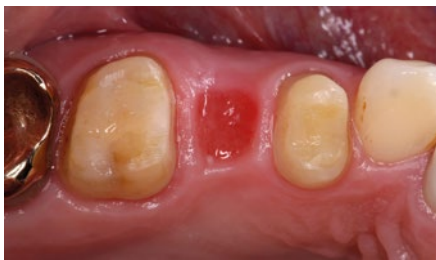

**Fig. 30** Postoperative situation after adhesive placement of the three-unit zirconia FDP with sintered ceramic veneer

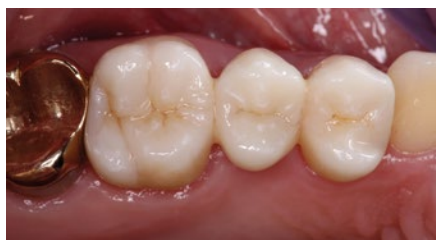of their high opacity, the first generation of zirconia was used predominantly as a framework material that was manually veneered by a sintering ceramic for aesthetic reasons. Specific material properties of zirconia in contrast to metal alloys, such as a different coefficient of thermal expansion and extreme low thermal conductivity, required new veneering materials and new firing parameters.<sup>78</sup> The combination of the optical properties of both the dentin-like zirconia framework and the enamel-like ceramic veneer greatly raised the aesthetic standards for metal-free FDPs in the anterior and posterior jaw (Figs 26, 27, 28, 29 and 30).<sup>79</sup> In clinical studies, the first generation of zirconia ceramics rarely exhibited framework fractures, but many cases of minor and major chipping of the veneer



**Fig. 31** Occlusal view of a CAD/CAM posterior three-unit FDP made of monolithic multilayer zirconia (3Y-TZP zirconia; Katana HT/ML, Kuraray Noritake, Tokyo, Japan). Surface staining was applied, without sintered ceramic veneer



**Fig. 32** Intraoral view of the prepared abutment teeth 14 and 16



**Fig. 33** Try-in of the three-unit FDP made of monolithic multilayer zirconia (3Y-TZP zirconia, Katana HT/ML; Kuraray Noritake)

as the most frequent complication.<sup>80,81,82</sup> In a randomised clinical trial (RCT), zirconia FDPs with up to five units demonstrated satisfying long-term results comparable to those of the metal ceramic control group.<sup>83</sup> Nevertheless, a higher rate of framework fractures, debonding, chipping and inferior marginal adaption was reported.

The use of monolithic zirconia would reduce the risk of chipping and improve the stability of the restoration while simplifying the CAD/CAM procedure.<sup>84</sup> One important prerequisite for using zirconia in monolithic restorations was improved aesthetics through reduced opacity and the option of individual staining. New formulas resulted in new types of zirconia ceramics with greater translucency.<sup>85</sup> Four generations of zirconia ceramics are now

available that can be differentiated by their admixture of aluminium and yttrium oxides. Not only their optical characteristics but also the mechanical properties are influenced as a result of a matter of changes in refractive index, grain size, and crystalline composition (Figs 31, 32 and 33).<sup>86,87</sup> Recently innovative CAD/CAM-materials were introduced, which combine two different zirconia compositions in one disc (gradient technology). New generations of zirconia ceramics promise new indications. All relevant long-term clinical trials refer to restorations made of 3Y-TZP zirconia. Many open questions remain, related especially to the third and fourth zirconia generations. Long-term clinical stability, wear behaviour and bonding options have not yet been fully verified.<sup>88</sup> Initial *in vitro* studies have demonstrated a significant increase of translucency in novel zirconia materials, but associated with a significant reduction in flexural strength.<sup>89</sup>

For 5Y-TZP zirconia, flexural strength and translucency parameters between those of 3Y-TZP and lithium disilicate ceramic are reported. Both the short-term and long-term bond strengths of 5Y-TZP and 3Y-TZP were shown to be similar to lithium disilicate. 5Y-TZP demonstrated no measurable material wear, and antagonist enamel wear was comparable to other materials tested.<sup>88</sup>

## Discussion

With the introduction of digital technologies and access to new restorative materials, clinicians are facing a continuously increasing range of treatment options in fixed prosthodontics. These options allow strategies and materials to be selected specifically for the individual patient's needs. However, clinicians and technicians need well-developed skills, experiences and knowledge to select the right therapy based on scientific data.

A paradigm shift towards less invasive treatment options is obvious; the overall aim is to reach the treatment goal while removing the least possible amount of natural tissue. Reliable bonding to natural enamel and tooth-coloured materials have ushered in a shift towards much more conservative preparation designs than was previously thought possible.<sup>4,5</sup>

Minimally invasive restorations are considered beneficial because of the low risk of damaging the pulp, better hard tissue protection, easier impression-taking, a better view of the site during preparation and

adhesive fixation, and less interference with the marginal gingiva. While these possibilities inspire a great deal of excitement, we should bear in mind that the methods described above involve a high degree of technique sensitivity regarding preparations (mainly enamel), adhesive bonding and fine-tuning of the static and dynamic occlusion.<sup>24,52,61,90,91</sup>

While clinical long-term studies<sup>10,13,46,47,91</sup> exist on minimally invasive restorative methods using ceramic materials, valid clinical data on the long-term behaviour of minimally invasive definitive restorations made of CAD/CAM composite resins are still lacking.<sup>92,93</sup> The intermediate three-year results of a five-year prospective clinical study with 45 inlays and 58 partial-coverage restorations made of CAD/CAM polymer-infiltrated ceramics have demonstrated good performance.<sup>94</sup> However, a significant decrease in marginal adaption and an increase in marginal discoloration and surface roughness were observed over time.<sup>94</sup> A randomised clinical trial with indirect composite resin and glass ceramic veneers showed similar survival rates of 87% and 93.5%, respectively. However, changes in surface characteristics were more frequent in the composite material.<sup>95</sup>

The clinical results with direct composites as a definitive restorative material were initially good, especially in the anterior region.<sup>96,97</sup> However, clinical follow-ups showed that in more complex cases, direct posterior composite restorations discernibly deteriorated after five and a half years and more, in terms of surface texture, anatomical shape and marginal fit.<sup>98</sup> The survival rates of composite resin as a restorative material in complex direct rehabilitations depend on the tooth position, being most unfavourable in the case of molars.<sup>99</sup>

Numerous *in vitro* studies on CAD/CAM composite resins and polymer-infiltrated ceramics have examined their optical and mechanical properties, surface and wear behaviour, as well as bonding options. In one of these *in vitro* studies, CAD/CAM composite resins showed higher flexural strengths than leucite ceramics and polymer-infiltrated ceramics, but lower strengths than lithium disilicate ceramics.<sup>100</sup> Glass ceramics showed lower discoloration rates than CAD/CAM composites and less two-body wear.<sup>100</sup> In multiple *in vitro* studies, ceramics showed superior gloss retention compared to hybrid ceramics, composites and acrylic polymers.<sup>101,102,103</sup>



Since ceramics are expected to exhibit lower wear than resin composites under clinical conditions, the long-term stability after an increase in the vertical dimension of occlusion in complex rehabilitations, where ceramics are used in the antagonist jaw, might be superior to that of resin composite materials.<sup>104,105</sup> Finally, because CAD/CAM composite resins show a high degree of conversion, a reliable bond to the internal surface of the restoration is difficult to achieve. A reliable bond to luting composites seems to be achieved only by air abrasion and special pre-treatment strategies.<sup>106</sup>

Despite the numerous *in vitro* studies on CAD/CAM composite resins and polymer-infiltrated ceramics, controlled, randomised clinical trials still remain the gold standard against which to compare the clinical performance of new materials. As a consequence, the authors still consider all-ceramic restorations the treatment of choice for definitive restorations, especially in complex rehabilitations where the masticatory forces are borne solely by the restorations. However, the preparations should be as minimally invasive as possible and developed individually in accordance with the chosen material and type of restoration.

According to the authors, clinical evidence for CAD/CAM composite resins is limited to single-tooth restorations with enamel margins within a functional masticatory system, where bite forces are additionally distributed to adjacent natural teeth. Here the use of a composite restoration can help preserve the natural tooth structure on the antagonistic dentition.<sup>100</sup>

## Conclusion

Dentists providing fixed prosthetic restorations have a vast array of treatment alternatives to conventional and, essentially, more invasive procedures. The introduction of digital technologies has paved the way for innovative treatment strategies and restorative concepts in terms of new diagnostic tools, benefits in communication and treatment planning, and access to new materials with extended indications. The introduction of new polymer materials supports innovative reversible pre-treatment concepts, such as: CAD/CAM tooth-coloured fully-contoured removable splints; and new CAD/CAM ceramics which provide new indications for definitive restorations. Many metal-free treatment modalities introduced in the last decades

are now backed up by valid long-term data. Regarding the material class of ceramics, the relevant treatment options are considered to be scientifically validated for numerous indications. On the other hand, sufficient long-term results on the use of CAD/CAM composite resins and polymer-infiltrated ceramics for definitive restorations and novel classes of zirconia are not available yet. Generally, the methods described in this article are technique-sensitive and therefore require the clinician and technician to have well-developed skills and experience. And with all that, the present report has only been able to touch upon a small section of the spectrum of present-day fixed prosthodontics.

## References

- Pjetursson B E, Lang N P. Prosthetic treatment planning on the basis of scientific evidence. *J Oral Rehabil* 2008; **35** (Spec Iss): 72–79.
- Cheung G S, Lai S C, Ng R P. Fate of vital pulps beneath a metal-ceramic crown or a bridge retainer. *Int Endod J* 2005; **38**: 521–530.
- Foster L V. Failed conventional bridge work from general dental practice: clinical aspects and treatment needs of 142 cases. *Br Dent J* 1990; **168**: 199–201.
- Edelhoff D, Sorensen J A. Tooth structure removal associated with various preparation designs for anterior teeth. *J Prosthet Dent* 2002; **87**: 503–509.
- Edelhoff D, Sorensen J A. Tooth structure removal associated with various preparation designs for posterior teeth. *Int J Periodontics Restorative Dent* 2002; **22**: 241–249.
- Al-Fouzan A F, Tashkandi E A. Volumetric measurements of removed tooth structure associated with various preparation designs. *Int J Prosthodont* 2013; **26**: 545–548.
- Chun Y H, Raffelt C, Pfeiffer H *et al*. Restoring strength of incisors with veneers and full ceramic crowns. *J Adhes Dent* 2010; **12**: 45–54.
- Soares P V, Santos-Filho P C, Martins L R, Soares C J. Influence of restorative technique on the biomechanical behavior of endodontically treated maxillary premolars. Part I: fracture resistance and fracture mode. *J Prosthet Dent* 2008; **99**: 30–37.
- Murphy F, McDonald A, Petrie A, Palmer G, Setchell D. Coronal tooth structure in root-treated teeth prepared for complete and partial coverage restorations. *J Oral Rehabil* 2009; **36**: 451–461.
- Kern M, Passia N, Sasse M, Yazigi C. Ten-year outcome of zirconia ceramic cantilever resin-bonded fixed dental prostheses and the influence of the reasons for missing incisors. *J Dent* 2017; **65**: 51–55.
- Jagodini S, Sasse M, Freitag-Wolf S, Kern M. Influence of attachment design and material on the retention of resin-bonded attachments. *Clin Oral Investig* 2019; **23**: 1217–1223.
- Guess P C, Selz C F, Steinhart Y N, Stampf S, Strub J R. Prospective clinical split-mouth study of pressed and CAD/CAM all-ceramic partial-coverage restorations: 7-year results. *Int J Prosthodont* 2013; **26**: 21–25.
- Beier U S, Kapferer I, Burtscher D, Dumfahrt H. Clinical performance of porcelain laminate veneers for up to 20 years. *Int J Prosthodont* 2012; **25**: 79–85.
- Fradeani M, Barducci G, Bacherini L, Brennan M. Esthetic rehabilitation of a severely worn dentition with minimally invasive prosthetic procedures (MIPP). *Int J Periodontics Restorative Dent* 2012; **32**: 135–147.
- Walls A W. The use of adhesively retained all-porcelain veneers during the management of fractured and worn anterior teeth: Part 2. Clinical results after 5 years of follow-up. *Br Dent J* 1995; **178**: 337–340.
- Loomans B, Opdam N, Attin T *et al*. Severe tooth wear: European consensus statement on management guidelines. *J Adhes Dent* 2017; **19**: 111–119.
- Edelhoff D, Schweiger J, Prandner O, Trimpl J, Stimmelmayer M, Güth J F. CAD/CAM splints for the functional & esthetic evaluation of new defined occlusal dimensions. *Quintessence Int* 2017; **48**: 181–191.
- Opdam N, Frankenberger R, Magne P. From 'direct versus indirect' toward an integrated restorative concept in the posterior dentition. *Oper Dent* 2016; **41** (Spec Iss): S27–S34.
- Edelhoff D, Ahlers M O. Occlusal onlays as a modern treatment concept for the reconstruction of severely worn occlusal surfaces. *Quintessence Int* 2018; **49**: 521–533.
- Edelhoff D, Prandner O, Saeidi Pour R, Liebermann A, Stimmelmayer M, Güth J F. Anterior restorations: The performance of ceramic veneers. *Quintessence Int* 2018; **49**: 89–101.
- Leib A M. Patient preference for light-cured composite bite splint compared to heat-cured acrylic bite splint. *J Periodontol* 2001; **72**: 1108–1112.
- Ahlers M O. Determination of vertical dimension when using repositioning onlays for second stage restorative treatment after functional therapy. *J Craniomandibular Function* 2014; **6**: 131–148.
- Edelhoff D, Beuer F, Schweiger J, Brix O, Stimmelmayer M, Güth J F. CAD/CAM-generated high-density polymer restorations for the pre-treatment of complex cases. *Quintessence Int* 2012; **43**: 457–467.
- Rouse J S. Full veneer versus traditional veneer preparation: A discussion of interproximal extension. *J Prosthet Dent* 1997; **78**: 545–549.
- Simonsen R J. From prevention to therapy: minimal intervention with sealants and resin restorative materials. *J Dent* 2011; **39** (Spec Iss): S27–S33.
- Stappert C F, Stathopoulou N, Gerds T, Strub J R. Survival rate and fracture strength of maxillary incisors, restored with different kinds of full veneers. *J Oral Rehabil* 2005; **32**: 266–272.
- Vailati F, Belser U C. Full-mouth adhesive rehabilitation of a severely eroded dentition: the three-step technique. Part 1. *Eur J Esthet Dent* 2008; **3**: 30–44.
- Vailati F, Belser U C. Full-mouth adhesive rehabilitation of a severely eroded dentition: the three-step technique. Part 2. *Eur J Esthet Dent* 2008; **3**: 128–146.
- Vailati F, Belser U C. Full-mouth adhesive rehabilitation of a severely eroded dentition: the three-step technique. Part 3. *Eur J Esthet Dent* 2008; **3**: 236–257.
- Belser U C, Magne P, Magne M. Ceramic laminate veneers: continuous evolution of indications. *J Esthet Dent* 1997; **9**: 197–207.
- Peumans M, van Meerbeek B, Lambrechts P, Vanherle G. Porcelain veneers: a review of the literature. *J Dent* 2000; **28**: 163–177.
- Walls A W. The use of adhesively retained all-porcelain veneers during the management of fractured and worn anterior teeth: Part 2. Clinical results after 5 years of follow-up. *Br Dent J* 1995; **178**: 337–340.
- Chu S J, Mielezko A J. Color-matching strategies for non-vital discolored teeth: part 1. Laboratory ceramic veneer fabrication solutions. *J Esthet Restor Dent* 2014; **26**: 240–246.
- Magne P, Douglas W H. Porcelain veneers: dentin bonding optimization and biomimetic recovery of the crown. *Int J Prosthodont* 1999; **12**: 111–121.
- Magne P, Douglas W H. Interdental design of porcelain veneers in the presence of composite fillings: finite element analysis of composite shrinkage and thermal stresses. *Int J Prosthodont* 2000; **13**: 117–124.
- Burke F J. Survival rates for porcelain laminate veneers with special reference to the effect of preparation in dentin: a literature review. *J Esthet Restor Dent* 2012; **24**: 257–265.
- Gurel G, Sesma N, Calamita M A, Coachman C, Morimoto S. Influence of enamel preservation on failure rates of porcelain laminate veneers. *Int J Periodontics Restorative Dent* 2013; **33**: 31–39.
- Schmidt K K, Chiayabutr Y, Phillips K M, Kois J C. Influence of preparation design and existing condition of tooth structure on load to failure of ceramic laminate veneers. *J Prosthet Dent* 2011; **105**: 374–382.
- Magne P, Douglas W H. Design optimization and evolution of bonded ceramics for the anterior dentition: a finite-element analysis. *Quintessence Int* 1999; **30**: 661–672.

40. Albanesi R B, Pigozzo M N, Sesma N, Laganá D C, Morimoto S. Incisal coverage or not in ceramic laminate veneers: A systematic review and meta-analysis. *J Dent* 2016; **52**: 1–7.
41. Faus-Matoses I, Solá-Ruiz F. Dental preparation with Sonic vs. high-speed Finishing: analysis of microleakage in bonded veneer restorations. *J Adhes Dent* 2014; **16**: 29–34.
42. Magne P, Belsler U. *Bonded Porcelain Restorations in the Anterior Dentition: A Biomimetic Approach*. New Malden: Quintessence, 2002.
43. Rieder C E. The use of provisional restorations to develop and achieve esthetic expectations. *Int J Periodontics Restorative Dent* 1989; **9**: 122–139.
44. Xu B, Chen X, Li R, Wang Y, Li Q. Agreement of try-in pastes and the corresponding luting composites on the final color of ceramic veneers. *J Prosthodont* 2014; **23**: 308–312.
45. Guess P C, Stappert C F. Midterm results of a 5-year prospective clinical investigation of extended ceramic veneers. *Dent Mater* 2008; **24**: 804–813.
46. Frankenberger R, Taschner M, Garcia-Godoy F, Petschelt A, Krämer N. Leucite-reinforced glass ceramic inlays and onlays after 12 years. *J Adhes Dent* 2008; **10**: 393–398.
47. van Dijken J W, Hasselrot L. A prospective 15-year evaluation of extensive dentinenamelbonded pressed ceramic coverages. *Dent Mater* 2010; **26**: 929–939.
48. Ma L, Guess P C, Zhang Y. Load-bearing properties of minimal-invasive monolithic lithium disilicate and zirconia occlusal onlays: finite element and theoretical analyses. *Dent Mater* 2013; **29**: 742–751.
49. Kreulen C M, van 't Spijker A, Rodriguez J M, Bronkhorst E M, Creugers N H J, Bartlett D W. Systematic review of the prevalence of tooth wear in children and adolescents. *Caries Res* 2010; **44**: 151–159.
50. Jaeggi T, Grüninger A, Lussi A. Restorative therapy of erosion. *Monogr Oral Sci* 2006; **20**: 200–214.
51. Magne P, Belsler U. Porcelain versus composite inlays/onlays: effect of mechanical loads on stress distribution, adhesion, and crown flexure. *Int J Periodontics Restorative Dent* 2003; **23**: 543–555.
52. Ahlers M O, Mörig G, Blunck U, Hajtő J, Pröbster L, Frankenberger R. Guidelines for the preparation of CAD/CAM ceramic inlays and partial crowns. *Int J Comput Dent* 2009; **12**: 309–325.
53. Frankenberger R, Taschner M, Garcia-Godoy F, Petschelt A, Krämer N. Leucite-reinforced glass ceramic inlays and onlays after 12 years. *J Adhes Dent* 2008; **10**: 393–398.
54. Rochette A L. Attachment of a splint to enamel of lower anterior teeth. *J Prosthet Dent* 1973; **30**: 418–423.
55. Briggs P, Dunne S, Bishop K. The single unit, single retainer, cantilever resin-bonded bridge. *Br Dent J* 1996; **181**: 373–379.
56. Hopkins C. An immediate cantilevered Rochette bridge. *Br Dent J* 1981; **151**: 292–295.
57. Botelho M G, Chan A W, Leung N C, Lam W Y. Long-term evaluation of cantilevered versus fixed-fixed resin-bonded fixed partial dentures for missing maxillary incisors. *J Dent* 2016; **45**: 59–66.
58. Wei Y R, Wang X D, Zhang Q *et al*. Clinical performance of anterior resin-bonded fixed dental prostheses with different framework designs: A systematic review and meta-analysis. *J Dent* 2016; **47**: 1–7.
59. Kern M, Sasse M. Ten-year survival of anterior all-ceramic resin-bonded fixed dental prostheses. *J Adhes Dent* 2011; **13**: 407–410.
60. Kern M. *RBFDPs: Resin-Bonded Fixed Dental Prostheses*. 1st ed. New Malden: Quintessence, 2018.
61. Sasse M, Kern M. All-ceramic resin-bonded fixed dental prostheses: treatment planning, clinical procedures, and outcome. *Quintessence Int* 2014; **45**: 291–297.
62. Lam W Y, McGrath C P, Botelho M G. Impact of complications of single tooth restorations on oral health-related quality of life. *Clin Oral Implants Res* 2014; **25**: 67–73.
63. Polder B J, Van't Hof M A, Van der Linden F P, Kuijpers-Jagtman A M. A meta-analysis of the prevalence of dental agenesis of permanent teeth. *Community Dent Oral Epidemiol* 2004; **32**: 217–226.
64. Stappert C F, Tarnow D P, Tan J H, Chu S J. Proximal contact areas of the maxillary anterior dentition. *Int J Periodontics Restorative Dent* 2010; **30**: 471–477.
65. Kern M, Schwarzbach W, Strub J R. Stability of all-porcelain, resin-bonded fixed restorations with different designs: an in vitro study. *Int J Prosthodont* 1992; **5**: 108–113.
66. Blatz M B, Vonderheide M, Conejo J. The effect of resin bonding on long-term success of high-strength ceramics. *J Dent Res* 2018; **97**: 132–139.
67. Inokoshi M, Van Meerbeek B. Adhesively luted zirconia restorations: why and how? *J Adhes Dent* 2014; **16**: 294.
68. Özcan M, Bernasconi M. Adhesion to zirconia used for dental restorations: a systematic review and meta-analysis. *J Adhes Dent* 2015; **17**: 7–26.
69. Sailer I, Hämmerle C H. Zirconia ceramic single-retainer resin-bonded fixed dental prostheses (RBFDPs) after 4 years of clinical service: a retrospective clinical and volumetric study. *Int J Periodontics Restorative Dent* 2014; **34**: 333–343.
70. Sailer I, Bonani T, Brodbeck U, Hämmerle C H. Retrospective clinical study of single-retainer cantilever anterior and posterior glass-ceramic resin-bonded fixed dental prostheses at a mean follow-up of 6 years. *Int J Prosthodont* 2013; **26**: 443–450.
71. Simeone P, Gracis S. Eleven-Year Retrospective Survival Study of 275 Veneered Lithium Disilicate Single Crowns. *Int J Periodontics Restorative Dent* 2015; **35**: 685–694.
72. Gehrt M, Wolfart S, Rafai N, Reich S, Edelhoff D. Clinical results of lithium-disilicate crowns after up to 9 years of service. *Clin Oral Investig* 2013; **17**: 275–284.
73. van den Breemer C R, Vinkenborg C, van Pelt H, Edelhoff D, Cune M S. The clinical performance of monolithic lithium disilicate posterior restorations after 5, 10, and 15 years: A retrospective case series. *Int J Prosthodont* 2017; **30**: 62–65.
74. Teichmann M, Göckler F, Wübbels A, Weber V, Yildirim M, Wolfart S, Edelhoff D. Ten-year survival and complication rates of lithium-disilicate (Empress 2) tooth-supported crowns, implant-supported crowns, and fixed dental prostheses. *J Dent* 2017; **56**: 65–77.
75. Sola-Ruiz M F, Lagos-Flores E, Roman-Rodriguez J L, Highsmith Jdel R, Fons-Font A, Granell-Ruiz M. Survival rates of a lithium disilicate-based core ceramic for three-unit esthetic fixed partial dentures: a 10-year prospective study. *Int J Prosthodont* 2013; **26**: 175–180.
76. Kern M, Sasse M, Wolfart S. Ten-year outcome of three-unit fixed dental prostheses made from monolithic lithium disilicate ceramic. *J Am Dent Assoc* 2012; **143**: 234–240.
77. Manicone P F, Rossi Iommetti P, Raffaelli L. An overview of zirconia ceramics: basic properties and clinical applications. *J Dent* 2007; **35**: 819–826.
78. Tholey M J, Swain M V, Thiel N. Thermal gradients and residual stresses in veneered Y-TZP frameworks. *Dent Mater* 2011; **27**: 1102–1110.
79. Pecho O E, Ghinea R, Ionescu A M, Cardona Jde L, Paravina R D, Pérez Mdel M. Color and translucency of zirconia ceramics, human dentine and bovine dentine. *J Dent* 2012; **40** (Spec Iss): e34–e40.
80. Heintze S D, Rousson V. Survival of zirconia and metal-supported fixed dental prostheses: a systematic review. *Int J Prosthodont* 2010; **23**: 493–502.
81. Ioannidis A, Bindl A. Clinical prospective evaluation of zirconia-based three-unit posterior fixed dental prostheses: Up-to ten-year results. *J Dent* 2016; **47**: 80–85.
82. Teichmann A, Wienert A L, Rückbeil M, Weber V, Wolfart S, Edelhoff D. Ten-year survival and chipping rates and clinical quality grading of zirconia-based fixed dental prostheses. *Clin Oral Investig* 2018; **22**: 2905–2915.
83. Sailer I, Balmer M, Hüslér J, Hämmerle C H F, Känel S, Thoma D S. 10-year randomized trial (RCT) of zirconia-ceramic and metal-ceramic fixed dental prostheses. *J Dent* 2018; **76**: 32–39.
84. Guess P C, Zavanelli R A, Silva N R, Bonfante E A, Coelho P G, Thompson V P. Monolithic CAD/CAM lithium disilicate versus veneered Y-TZP crowns: comparison of failure modes and reliability after fatigue. *Int J Prosthodont* 2010; **23**: 434–442.
85. Zhang Y, Lawn B R. Novel zirconia materials in dentistry. *J Dent Res* 2018; **97**: 140–147.
86. Stawarczyk B, Keul C, Eichberger M, Figge D, Edelhoff D, Lümekmann N. Three generations of zirconia: From veneered to monolithic. Part I. *Quintessence Int* 2017; **48**: 369–380.
87. Stawarczyk B, Keul C, Eichberger M, Figge D, Edelhoff D, Lümekmann N. Three generations of zirconia: From veneered to monolithic. Part II. *Quintessence Int* 2017; **48**: 441–450.
88. Sailer I, Strasding M, Valente N A, Zwahlen M, Liu S, Pjetursson B E. A systematic review of the survival and complication rates of zirconia-ceramic and metal-ceramic multiple-unit fixed dental prostheses. *Clin Oral Implants Res* 2018; **29** (Spec Iss): 184–198.
89. Kwon S J, Lawson N C, McLaren E E, Nejat A H, Burgess J O. Comparison of the mechanical properties of translucent zirconia and lithium disilicate. *J Prosthet Dent* 2018; **120**: 132–137.
90. Frankenberger R, Reinelt C, Petschelt A, Krämer N. Operator vs. material influence on clinical outcome of bonded ceramic inlays. *Dent Mater* 2009; **25**: 960–968.
91. Beier U S, Kapferer I, Dumfahrt H. Clinical long-term evaluation and failure characteristics of 1: 335 all-ceramic restorations. *Int J Prosthodont* 2012; **25**: 70–78.
92. Fasbinder D J, Dennison J B, Heys D R, Lampe K. The clinical performance of CAD/CAM-generated composite inlays. *J Am Dent Assoc* 2005; **136**: 1714–1723.
93. Vanoorbeek S, Vandamme K, Lijnen I, Naert I. Computer-aided designed/computer-assisted manufactured composite resin versus ceramic single-tooth restorations: a 3-year clinical study. *Int J Prosthodont* 2010; **23**: 223–230.
94. Spitznagel F A, Scholz K J, Strub J R, Vach K, Gierthmuehlen P C. Polymer-infiltrated ceramic CAD/CAM inlays and partial coverage restorations: 3-year results of a prospective clinical study over 5 years. *Clin Oral Investig* 2018; **22**: 1973–1983.
95. Gresnigt M M, Kalk W, Özcan M. Randomized clinical trial of indirect resin composite and ceramic veneers: up to 3-year follow-up. *J Adhes Dent* 2013; **15**: 181–190.
96. Schmidlin P R, Füll T, Imfeld C, Tepper S, Attin T. Three-year evaluation of posterior vertical bite reconstruction using direct resin composite case series. *Oper Dent* 2009; **34**: 102–108.
97. Wolff D, Kraus T, Schach C *et al*. Recontouring teeth & closing diastemas with direct composite buildups: a clinical evaluation of survival and quality parameters. *J Dent* 2010; **38**: 1001–1009.
98. Attin T, Füll T, Imfeld C, Schmidlin P R. Composite vertical bite reconstructions in eroded dentitions after 5.5 years: a case series. *J Oral Rehabil* 2012; **39**: 73–79.
99. Loomans B A C, Kreulen C M, Huijs-Visser H E C E *et al*. Clinical performance of full rehabilitations with direct composite in severe tooth wear patients: 3.5 Years results. *J Dent* 2018; **70**: 97–103.
100. Stawarczyk B, Liebermann A, Eichberger M, Güth J F. Evaluation of mechanical and optical behavior of current esthetic dental restorative CAD/CAM composites. *J Mech Behav Biomed Mater* 2015; **55**: 1–11.
101. Partin-Agarwal K, Terwilliger R J, Lien W, Jessup J P, Motyka N C, Vandewalle K S. Polish retention of ceramic-polymer CAD/CAM materials. *Gen Dent* 2018; **66**: 65–70.
102. Koizumi H, Saiki O, Nogawa H, Hiraba H, Okazaki T, Matsumura H. Surface roughness & gloss of current CAD/CAM resin composites before & after toothbrush abrasion. *Dent Mater J* 2015; **34**: 881–887.
103. Mörmann W H, Stawarczyk B, Ender A, Sener B, Attin T, Mehl A. Wear characteristics of current aesthetic dental restorative CAD/CAM materials: two-body wear, gloss retention, roughness and Martens hardness. *J Mech Behav Biomed Mater* 2015; **55**: 113–125.
104. Matzinger M, Hahnel S, Preis V, Rosentritt M. Polishing effects and wear performance of chairside CAD/CAM materials. *Clin Oral Investig* 2019; **23**: 725–737.
105. D'Arcangelo C, Vanini L, Rondoni G D, Vadini M, De Angelis F. Wear Evaluation of Prosthetic Materials Opposing Themselves. *Oper Dent* 2018; **43**: 38–50.
106. Reymus M, Roos M, Eichberger M, Edelhoff D, Hickel R, Stawarczyk B. Bonding to new CAD/CAM resin composites: influence of air abrasion and conditioning agents as pretreatment strategy. *Clin Oral Investig* 2019; **23**: 529–538.